

## Atypical *Mycobacterium* furunculosis occurring after pedicures

Kelley Pagliai Redbord, MD,<sup>a</sup> David A. Shearer, MD,<sup>f</sup> Hugh Gloster, MD,<sup>a</sup> Bruce Younger, MD,<sup>b</sup>  
Beverly L. Connelly, MD,<sup>c</sup> Susan E. Kindel, MD,<sup>d</sup> and Anne W. Lucky, MD<sup>a,c</sup>  
*Cincinnati, Ohio, and Florence, Kentucky*

*Mycobacterium fortuitum* complex are rapidly-growing nontuberculous mycobacteria found ubiquitously in the environment including, water, soil, dust, and biofilms. *M fortuitum* has been reported to cause skin and soft-tissue infections in association with nail salon footbath use during pedicures. Four cases of *M fortuitum* complex furunculosis are reported that occurred after pedicures in the Cincinnati, Ohio/Northern Kentucky area. Dermatologists and clinicians should consider mycobacterial infections from the *M fortuitum* complex when patients present with nonhealing furuncles on the lower legs and should inquire about recent pedicures. Early recognition and institution of appropriate therapy are critical. Public health measures should be explored to protect against such infections, given the recent popularity of the nail care industry. (J Am Acad Dermatol 2006;54:520-4.)

Nontuberculous mycobacteria are increasingly being recognized in human disease. *Mycobacterium fortuitum* complex (*M fortuitum* group and *Mycobacterium chelonae/abscessus* group) account for the majority of skin and soft tissue infections in the United States. These are rapidly-growing mycobacteria found ubiquitously in the environment, including water, soil, dust, and biofilms.<sup>1,2</sup> These organisms can grow in municipal water systems and in distilled water and are resistant to sterilizers (eg, 2% formaldehyde and alkaline glutaraldehyde), antiseptics (eg, mercury and thimerosal), and other standard disinfectants, such as chlorine.<sup>1</sup> Nosocomial disease outbreaks have been reported and include surgical wound infections, postinjection abscesses, and infections following endoscopy with contaminated scopes.<sup>1</sup> Three case reports of mycobacterial infections have been

reported following pedicures, which coincides with the recent popularity of the nail salon industry.<sup>3-5</sup> In this article, 4 additional cases of *M fortuitum* complex furunculosis are reported following pedicures in 3 different salons in the Cincinnati, Ohio/Northern Kentucky area.

### CASE REPORTS

#### Case 1

A 22-year-old otherwise healthy white woman was referred for evaluation of “bug bites.” The patient reported a 3- to 4-month history of tender nodules draining purulent material limited to the front and sides of her lower legs. The patient had been treated with a 10-day course of amoxicillin and Neosporin ointment without improvement. She denied using hot tubs or swimming in a pool or lake preceding the eruption. She had been taking oral contraceptives for 4 months, but had discontinued them 2 weeks before presentation. She reported frequent pedicures at the same nail salon, the last pedicure being 3 months before presentation. The patient also gave a history of shaving her legs the night before each pedicure. She took no other medications, had a negative review of systems, and no significant medical history.

On physical examination, involving both the front and sides of her lower legs, there were multiple, nontender, perifollicular, erythematous to violaceous papules and nodules, some of which were crusted and peripherally erythematous (Fig 1).

The patient was first diagnosed with staphylococcal folliculitis and furunculosis and started on a regimen of cefadroxil, 500 mg twice daily for 10 days;

From the Department of Dermatology, College of Medicine, University of Cincinnati<sup>a</sup>; Volunteer Clinical Assistant Professor, University of Cincinnati<sup>b</sup>; Division of Infectious Diseases, Cincinnati Children's Hospital Medical Center<sup>c</sup>; Richfield Dermopath Diagnostics, Cincinnati<sup>d</sup>; Division of Pediatric Dermatology, Cincinnati Children's Hospital Medical Center and Dermatology Associates of Cincinnati<sup>e</sup>; and The Dermatology Center, Florence.<sup>f</sup>

Funding sources: None.

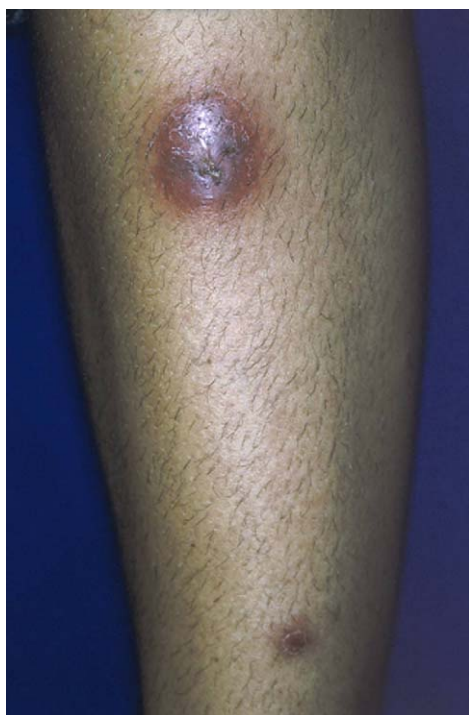Conflicts of interest: None identified.

Reprint requests: Anne W. Lucky, MD, Division of Pediatric Dermatology, Cincinnati Children's Hospital Medical Center, 3333 Burnet Ave, Cincinnati, OH 45229. E-mail: [anne.lucky@cchmc.org](mailto:anne.lucky@cchmc.org).

0190-9622/\$32.00

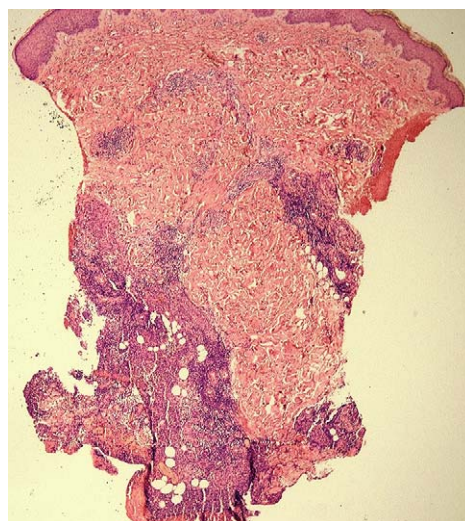
© 2006 by the American Academy of Dermatology, Inc.

doi:10.1016/j.jaad.2005.10.018

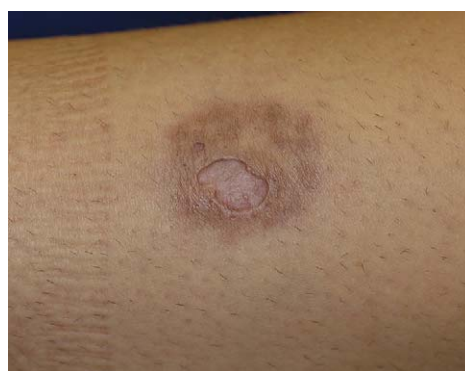

**Fig 1.** Case 1. Nodules on shin with crusting and peripheral erythema.

chlorhexidine cleanser and mupirocin ointment. A bacterial culture was performed and reported as negative. The patient's condition continued to flare despite treatment. Consequently, a 3-mm punch biopsy specimen was obtained and the resultant copious purulent material was sent for culture. The biopsy finding was most consistent with furunculosis with a neutrophilic and granulomatous infiltrate clustered around hair follicles (Fig 2). Bacterial culture of the purulent material was again negative. The patient continued to worsen with the appearance of new violaceous nodules. Two additional 3-mm punch biopsy specimens were obtained, one for histopathology and one for culture for atypical microbacteria and fungal and anaerobic organisms. The repeat biopsy finding was consistent with a furuncle or carbuncle with negative periodic acid-Schiff and acid-fast bacilli (AFB) stains. After 1 month, the AFB cultures were found to be positive for *M fortuitum/peregrinum* group. The patient was started on a regimen of clarithromycin, 500 mg twice daily, and rifampin, 300 mg once daily. When sensitivities became available showing intermediate susceptibility to clarithromycin, the patient's regimen was switched from clarithromycin to doxycycline, 100 mg twice daily for a 6-week course. Upon follow-up, the patient had improved but still complained of purple-brown discoloration and scarring at the sites of the previous lesions (Fig 3).



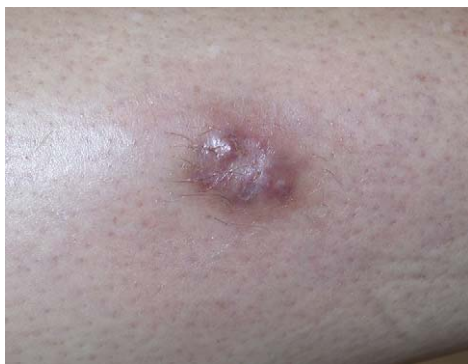**Fig 2.** Case 1. Histopathologic specimen from a 3-mm punch biopsy shows neutrophilic and granulomatous infiltrate clustered around hair follicle. (Hematoxylin-eosin stain; original magnification  $\times 4$ .)



**Fig 3.** Case 1. Discoloration and scarring at the sites of a previously active furuncle after completion of double antibiotic therapy.

## Case 2

A 27-year-old otherwise healthy white woman presented with a 6-month history of multiple, tender, violaceous nodules on her lower legs. The patient had been previously diagnosed and treated by her primary care doctor for presumed folliculitis. A nodule was incised and drained and the expressed purulent material was sent for routine bacterial culture, which was negative. The patient was subsequently treated with minocycline, 100 mg twice daily, and returned with more violaceous, erythematous nodules on her lower legs. She reported regular monthly or bi-monthly pedicures and shaving the night before each of her appointments. A punch biopsy specimen and AFB and fungal cultures were obtained. Treatment was initiated for presumed atypical mycobacterial infection with clarithromycin, 500 mg twice



**Fig 4.** Case 3. Follow-up examination showed some improvement with residual scarring at sites of previous lesions.

daily, and trimethoprim-sulfamethoxazole DS twice daily. The AFB culture was positive for *M chelonae/fortuitum* and was not further classified; sensitivities were not obtained to guide therapy. The patient could not tolerate the twice-daily dosing of the medications because of gastrointestinal side effects and was switched to once-daily dosing. She improved but continued to complain of draining abscesses, which all resulted in hypopigmented to violaceous scars. Antibiotic therapy was continued until all the lesions were healed, a total of 5 months.

### Case 3

A 28-year-old otherwise healthy white woman was referred for evaluation of “bug bites” on both legs. The patient reported a 9-month history of nonhealing, draining, asymptomatic nodules on both shins. She reported frequent pedicures every 3 weeks at the same nail salon 1 month before the appearance of the nodules. She visited the same nail salon as the patient described in case 1. The patient also reported shaving her legs the night before each pedicure. The patient was started on a regimen of doxycycline, 100 mg twice daily, for presumed atypical mycobacterial infection.

On physical examination, involving both anterior lower legs were multiple nontender, perifollicular, erythematous to violaceous nodules and plaques. Two punch biopsy specimens were obtained, one for histopathology and one for tissue culture to rule-out AFB and deep fungal infections. Histology showed a ruptured hair follicle with adjacent fibrosis and a mixed infiltrate representing superficial folliculitis. Gomori’s methenamine silver and AFB stains for fungi and mycobacteria were negative. Tissue culture revealed *M fortuitum/peregrinum* group after 17 days.

Given susceptibility results, the patient was treated with doxycycline for 6 months. On follow-up,

the lesions improved with residual scarring at the sites of the previous lesions (Fig 4).

### Case 4

A 31-year-old otherwise healthy white woman presented with a 6-week history of one nontender, nondraining, erythematous, firm nodule on her left lower leg. She reported frequent pedicures every month for the last year at the same nail salon. The patient also gave a history of shaving her legs the night before each pedicure.

On physical examination, involving the left lower leg was a solitary, nontender, erythematous to violaceous, perifollicular, smooth, firm nodule. A punch biopsy specimen was obtained for tissue culture to rule-out AFB and deep fungal infections. Tissue culture revealed *M fortuitum* after 1 month.

The patient was treated with minocycline for 2 months. On follow-up, the lesion resolved with residual scarring.

### DISCUSSION

Unlike *M chelonae/abscessus* infections that occur in compromised hosts, *M fortuitum* disease most commonly occurs in otherwise healthy individuals. There have been 3 previous reports of *M fortuitum* causing skin and soft-tissue infections in association with nail salon footbath use during pedicures (Table I).<sup>3-5</sup> In 2002, Winthrop et al<sup>3</sup> reported the first large community outbreak of *M fortuitum* furunculosis following footbath use at a nail salon in northern California. One hundred ten customers were identified with furunculosis; 34 had positive cultures for rapidly growing mycobacteria, with 32 being *M fortuitum*. In 2003, Snizek et al<sup>4</sup> reported 3 cases of *M chelonae* and *M fortuitum* causing infections following pedicures in southern California. In 2004, Gira et al<sup>5</sup> reported two cases of lower extremity furunculosis caused by *Mycobacterium mageritense* following pedicures in Georgia. It is very likely that mycobacterial infections following pedicures are more widespread in the United States and often underrecognized.

To determine the prevalence of mycobacteria in whirlpool footbaths, Vugia et al<sup>6</sup> found that 29 of 30 surveyed spas in California grew positive mycobacteria isolates, *M fortuitum* being the most prevalent. Pathogenic mycobacteria are widespread in salon footbaths.

Mycobacterial furunculosis is characterized by a severe, protracted course that frequently results in scarring. There is usually a delay in seeking medical attention given the initial benign, nodular appearance of these lesions. In addition, there is often a

**Table I.** Reported cases of nontuberculous mycobacterial furunculosis after pedicure

Authors	Year	Location	No. of patients	Shaved legs	Organisms	Sensitivities
Winthrop et al <sup>3</sup>	2002	Northern California	34	70%	<i>M fortuitum</i> (32) Unidentified (2)	None
Sniezek et al <sup>4</sup>	2003	Southern California	3	66.6%	<i>M chelonae</i>	S: Clarithromycin, ciprofloxacin I: TMP-SMX
					<i>M. fortuitum</i>	S: Clarithromycin, TMP-SMX, amikacin, ciprofloxacin
Gira et al <sup>5</sup>	2004	Atlanta, Georgia	2	100%	<i>M mageritense</i>	S: Amikacin, imipenem, sulfamethoxazole, fluoroquinolones, linezolid R: Clarithromycin
Current study	2005	Cincinnati, Ohio/ Northern Kentucky	4	100%	<i>M fortuitum</i> / <i>peregrinum</i>	S: Amikacin, imipenem, doxycycline, ciprofloxacin, gatifloxacin, moxifloxacin, trimethoprim/sulfa I: Clarithromycin, ceftioxin R: Tobramycin, azithromycin
					<i>M chelonae</i> / <i>fortuitum</i>	None
					<i>M fortuitum</i>	None
<b>Total</b>			43	74.4%		

I, Intermediate; R, resistant; S, susceptible; TMP-SMX, trimethoprim-sulfamethoxazole.

delay in the diagnosis of atypical mycobacterial infection due to lack of suspicion by the provider. Skin trauma serves as a portal of entry for these ubiquitous organisms. Lesions typically resemble folliculitis or panniculitis and usually arise within 1 to 2 months after inoculation.<sup>3,7</sup> Histologically, lesions are characterized by tuberculoid, poorly formed granulomas, nonspecific chronic inflammation, and suppuration.

The diagnosis of *M fortuitum* infection from material that has not been aseptically collected is challenging. A variety of skin contaminants can rapidly overgrow the slower growing mycobacteria in routine cultures of exudate from lesions. With selective culture medium and optimal incubation conditions, recovery can be maximized. Broth-based mycobacterial culture systems may increase the yield. Acid fast staining of lesion exudates and skin biopsy specimens are not very helpful and frequently yield false negative results, as noted in our cases and in the literature. Therefore culture of punch biopsy specimens is believed optimal for diagnosis.<sup>4</sup>

Optimal treatment of *M fortuitum* furunculosis is not clear. Early administration of antimicrobial therapy has been shown to decrease disease duration in more severe diseases, but infections can be self-limited and heal without therapy.<sup>4,8</sup> Antibiotic choices should be guided by susceptibility results, given the frequency of varying susceptibility patterns. Isolates of *M fortuitum* are usually susceptible

to amikacin, imipenem-cilastatin, quinolones, and sulfonamides with varying susceptibility to doxycycline, and ceftioxin.<sup>9</sup> Unlike *M chelonae* group organisms, only about 35% of *M fortuitum* isolates are clarithromycin susceptible.<sup>10</sup> The optimal duration of antibiotic therapy is unknown, but 6 months or more of therapy may be required. Dual-agent therapy may overcome drug resistance. For *M fortuitum*, doxycycline, trimethoprim-sulfamethoxazole, and ciprofloxacin are useful oral agents for empiric therapy, pending susceptibility studies. Surgical drainage or resection is not usually necessary except in recalcitrant, deep lesions.

Of note, all of our patients reported shaving their legs the night before their pedicures. Winthrop et al<sup>3</sup> showed that 70% of patients with furunculosis reported prior leg shaving. Sniezek et al<sup>4</sup> reported leg shaving in 2 of 3 patients with mycobacterial furunculosis before the pedicure. In a report by Gira et al,<sup>5</sup> both patients shaved their legs before the pedicure. Thus it seems likely that microtrauma from shaving creates a portal of entry for the organisms within the contaminated footbaths.

In this article, 4 cases of *M fortuitum* furunculosis are reported that occurred after pedicures at 3 different salons in the Cincinnati, Ohio/Northern Kentucky region. A few cases of *M fortuitum* furunculosis following pedicures have been reported in the literature. Outbreaks of *M fortuitum* infection are likely sporadic and underrecognized by health care providers. Dermatologists and clinicians should



consider mycobacterial infections and inquire about recent pedicures in patients with apparent lower-extremity furunculosis. Tissue cultures and sensitivity studies should be performed to guide treatment, given the widespread antibiotic resistance of mycobacteria species. Early recognition of the organisms and institution of appropriate therapy are critical. Physicians and the public need to be educated about the possibility of infections following pedicures, and physicians should inquire about pedicures when faced with nonhealing furunculosis of the lower legs. Public health measures should be explored to protect against such infections given the recent increase in popularity of the nail care industry.

## REFERENCES

1. Wallace RJ, Brown BA, Griffith DE. Nosocomial outbreaks/pseudo outbreaks caused by nontuberculous mycobacteria. *Annu Rev Microbiol* 1998;52:453-90.
2. Palenque E. Skin disease and nontuberculous atypical mycobacteria. *Int J Dermatol* 2000;39:659-66.
3. Winthrop KL, Abrams M, Yakrus M, Schwartz I, Ely J, Gillies D, Vugia DJ. An outbreak of mycobacterial furunculosis associated with footbaths at a nail salon. *N Engl J Med* 2002;346:1366-71.
4. Sniezek PJ, Graham BS, Busch HB, Lederman ER, Lim ML, Poggemyer K, et al. Rapidly growing mycobacterial infections after pedicures. *Arch Dermatol* 2003;139:629-34.
5. Gira AK, Reisenauer AH, Hammock L, Nadaminte U, Macy JT, Reeves A, et al. Furunculosis due to *Mycobacterium mageritense* associated with footbaths at a nail salon. *J Clin Microbiol* 2004;42:1813-7.
6. Vugia DJ, Jang Y, Zizek C, Ely J, Winthrop KL, Desmond E, et al. Mycobacteria in nail salon whirlpool footbaths, California. *Emerg Infect Dis* 2005;11:616-8.
7. Rotman DA, Blauvelt A, Kerdel FA. Widespread primary cutaneous infections with *Mycobacterium fortuitum*. *Int J Dermatol* 1993;32:512-4.
8. Winthrop KL, Albridge K, South D, Albrecht P, Abrams M, Samuel MC, et al. The clinical management and outcome of nail salon-acquired *Mycobacterium fortuitum* skin infection. *Clin Infect Dis* 2004;38:38-44.
9. Wallace RJ Jr, Glassroth J, Griffith DE, Olivier KN, Cook JL, Gordin F. Diagnosis and treatment of disease caused by nontuberculous mycobacteria: American Thoracic Society Statement. *Am J Respir Crit Care Med* 1997;156(Suppl): S1-25.
10. Brown BA, Wallace RJ Jr, Onyi GO, De Rosas V, Wallace RJ 3rd, et al. Activities of four macrolides, including clarithromycin, against *Mycobacterium fortuitum*, *Mycobacterium chelonae*, and *M. chelonae*-like organisms. *Antimicrob Agents Chemother* 1992;36:180-4.

---

## Topical photodynamic therapy for primary cutaneous B-cell lymphoma: A pilot study

Maira Mori, MD,<sup>b</sup> Piero Campolmi, MD,<sup>b</sup> Luciano Mavilia, MD,<sup>b</sup> Riccardo Rossi, MD,<sup>b</sup>  
Pietro Cappugi, MD,<sup>b</sup> and Nicola Pimpinelli, MD<sup>a</sup>  
*Florence, Italy*

Photodynamic therapy (PDT) is a treatment based on the accumulation of a photosensitizer in the target cells and their selective destruction by irradiation with visible light. In the past 10 years, several patients with cutaneous T cell lymphoma have been successfully treated. The use of PDT in cutaneous B cell lymphoma has not been reported to date. We report the successful PDT treatment of 3 patients with early primary cutaneous B cell lymphoma. (*J Am Acad Dermatol* 2006;54:524-6.)

---

From the Department of Dermatological Sciences<sup>a</sup> and the Physical Therapy Unit,<sup>b</sup> University of Florence Medical School.

Funding sources: Supported by the Ministero dell'Istruzione, Università e Ricerca (MIUR) and the Ente Cassa di Risparmio di Firenze.

Conflicts of interest: None identified.

Reprint requests: Nicola Pimpinelli, MD, Department of Dermatological Sciences, University of Florence, Via della Pergola, 58/64, 50121 Florence, Italy. E-mail: [pimpi@unifi.it](mailto:pimpi@unifi.it).

0190-9622/\$32.00

© 2006 by the American Academy of Dermatology, Inc.

doi:10.1016/j.jaad.2005.10.016

**I**ndolent primary cutaneous B-cell lymphomas (CBCL), that is, follicular center and marginal zone lymphoma according to the European Organization for Research and Treatment of Cancer<sup>1</sup> (EORTC) and the recent consensus World Health Organization—EORTC classification,<sup>2</sup> are characterized by mostly local or regional extension and very good prognosis (rare extracutaneous spread, despite relatively frequent cutaneous relapses, and 5-year survival rate >95%). Both types are highly responsive to local radiotherapy (RT).<sup>2</sup> Small, isolated